

The Three Phases Of Bovine Laminitis

By Dr. Steven L. Berry, University of California Davis, Davis, Calif.

Reprinted from the Hoof Trimmers Association Inc.'s March 2001 newsletter.

Laminitis refers to a condition that impairs the circulation in the horn-producing tissues of the foot (corium). Coriosis might be a better term for the disease since more than the laminae, which produce new horn, are involved and laminitis lesions develop in other locations on the claw. The disease results in the hoof producing poor-quality horn, which leads to increased injury from concussion and other causes.

There are various forms of laminitis: acute or subacute, subclinical and chronic. *Acute or subacute* laminitis is a rare occurrence and is usually due to a single, gross metabolic insult such as a grain overload or diseases like metritis (retained placenta) or mastitis. It develops rapidly and causes severe signs of acute pain, but does not produce lesions that are visible in the hoof.

Subclinical laminitis is a multifactorial disease, meaning several factors work together to cause it, with lesions first visible about six to eight weeks after distinct insults. Recently, veterinary researchers have discussed whether subclinical laminitis really occurs or we do not see lesions because we are not looking carefully enough? *Chronic* laminitis develops from continuous or repeated insults that cause lesions that affect the shape and function of the feet and eventually locomotion.

The Three-phase Theory

Early theories on the pathogenesis or nature of laminitis in cattle hypothesized the cattle disease was similar to laminitis in horses, which is a disturbance to the corium's microcirculation followed by degenerative changes at the dermal-epidermal (corium-horn) junction. Drs. Peter Ossent and C. Lischer from Switzerland developed a detailed theory after examining the claws of post-mortem animals with clinical laminitis. The lesions they found ranged from impaired horn production with diffuse softening, discoloration and hemorrhages in the horn of

the sole, heel, and white line, to gradual development of double soles, heels and walls with white-line fissures, and eventually sole, toe and heel ulcers. In chronic cases the whole claw becomes deformed.

Their theory on the nature of laminitis divides the disease into three phases. During phase one vascular disturbances in the corium lead to degenerated dermal-epidermal junction.

The precise cause that induces laminitis in cattle is unknown. Researchers think vasoactive substances, possibly histamines and/or endotoxins, trigger pathological (disease) responses in the corium's blood vessels. The vessels dilate and their walls become paralyzed, making blood stagnate. The venous arterial shunts open and shunt or move the pooled blood away from the corium. The blood vessels in the corium develop hypoxia (a decrease in oxygen) and, possibly react by inflaming. Vessel walls become permeable and allow blood to seep out, which leads to edema and hemorrhage. Large, dark red patches develop in the normally pink corium, particularly in the laminae.

The soft tissues in the hoof are particularly vulnerable to the edema (an abnormal accumulation of fluid in cells, tissues or cavities, resulting in swelling) since the corium is trapped between the horn capsule and the pedal bone (distal phalanx). A vicious cycle develops that causes further damage and increased pain. Subclinical laminitis is thought to be chronic phase one. The horn is of inferior quality and diffusely softened with a yellow to hemorrhagic discoloration at the sole and white line. The cow is not usually lame during subclinical laminitis.

Blood vessels supply the corium's horn-producing cells with nutrients and oxygen. When the blood flow to this tissue decreases, the corium starts producing inferior-quality horn. This is especially critical at the dermal-

epidermal junction (white line) where the lamellar horn of the white line and the lamellar corium connect the pedal bone to the wall, because this lamellar area suspends a considerable part of the cow's weight. (See Figure 1). When the lamellar-lamellar junction fails and the interdigitation separates, the pedal bone sinks in the claw, putting even more pressure on the already compromised corium. This is phase 2 of laminitis, according to this theory.

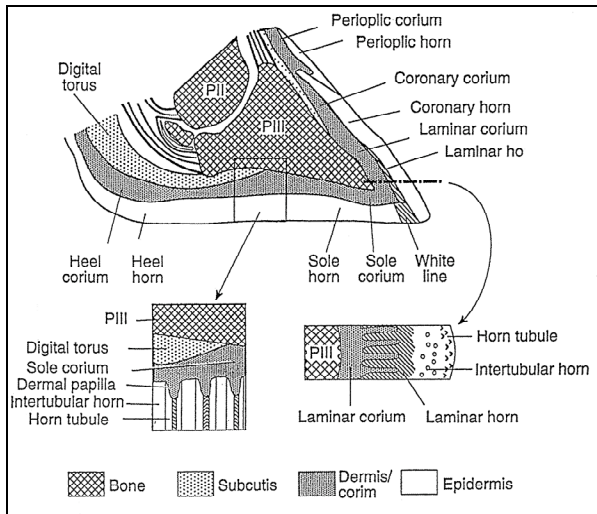


Figure 1: Diagram of vertical section through bovine claw. Digital torus is the digital cushion.

Pedal Bone Sinks In Phase Two

As the laminitis progresses the white line becomes disrupted and starts to separate. The pedal bones sink inside the horn capsule and puts more pressure on the sole and heel corium. Once the pedal bone sinks the situation is irreversible. The early stages of phase two have no overt, clinical signs although several weeks may have passed since onset. Prolonged compression of sole and heel corium lead to more capillary damage, hemorrhage, blood coagulating in vessels (thrombosis), inflammatory response, and tissue dying from a loss of blood (necrosis). Lesions are generally focal, exquisitely painful and can cause lameness.

A specific sign of a sinking pedal bone is a groove in the corium along the edge of the sole and a corresponding ridge in the inner horn along the junction between the sole and wall of the horn capsule.

Lesions Develop In Phase Three

Several weeks pass from onset of laminitis until clinical signs and lesions become visible. This is one reason why for many years we considered the many lesions to be separate diseases. Some of the changes seen in the chronically deformed hoof are from repeated episodes of laminitis.

The following laminitis lesions all stem from the inferior horn that the corium produced, which take time to appear on the surface of the hoof. Also, most of these lesions will not be visible until one pares away sole horn.

Yellow, soft horn

Serum escapes from the damaged corium and incorporates into the horn, producing a yellowish color. This damaged horn is softer and often more friable than normal horn and is one of the primary signs of chronic, subclinical laminitis.

Hemorrhage

If damage to the corium is more severe, blood leaks from the damaged vessels and incorporates in the horn tubules or lamellar horn. Then a hemorrhage will appear on the surface of the sole and heel approximately six weeks later. A white-line hemorrhage might take longer to appear if it develops farther up the wall. Repeated incidences of laminitis will manifest in different layers of hemorrhage in the horn.

Double sole

If the insult is more severe than to cause a simple hemorrhage it might lead to an accumulation of cellular debris on the surface of newly produced horn, which will manifest as a double sole or sole separation as it grows toward the surface. If the layers in the heel separate as the horn grows, it can under run the heel and provide an entrance for infection.

White-line disease

As the lamellar corium is damaged and produces inferior horn in the wall it can widen and weaken the white line as the horn grows out. The horn of the white line is the softest type of horn, making it relatively easy for fissures to form. If the fissures are deep enough, infection can occur, which may eventually work its way

up to the coronary band and form a white-line abscess. The abscess breaks through at the coronary band whereas the white-line lesion found when trimming the sole might be very small.

Sole or toe ulcer

Damage to the sole corium may be severe enough that the horn is of such poor quality that the lesion extends through the whole thickness of the sole or toe. When this occurs, the animal is usually three-legged lame. The most common site for a sole ulcer is on the rear, lateral claw beneath the flexor tuberosity of the pedal bone approximately at the junction of the sole and heel, which is referred to as the typical sole-ulcer site.

Deformed Claws

Deformed claws are the result of chronic laminitis, which causes horizontal (hardship) grooves, concave dorsal and abaxial walls, and a bulged or dropped sole. Many of these cows would not be described as clinically lame, but if you watch them walk and were to assign a locomotion score from the Michigan State University Lameness Scoring System, many of them would score 3 on a 1–5 scale. By the time the whole claw capsule is deformed, it is unlikely that hoof trimming can return it to

normal shape and function.

By sharing this three-phase theory of laminitis I hope I have helped many of you develop a better understanding of what laminitis is, as it is a confusing disease that has challenged many of us in the hoof care field. Next time I will discuss the risk factors that predispose cows to laminitis and how to prevent them.

References

A list of references is available from the author.

Figure Credit

Figure 1 reproduced from Susan Kempson, Definition of Laminitis, 10th International Symposium of Lameness in Ruminants Proceedings, Lucerne, Switzerland, 1998.

About The Author

Steven Berry, DVM, MPVM, is an extension dairy management and health specialist with the department of animal sciences at the University of California Davis and a member of the University's Footwart Task Force. He is also an active member of the Hoof Trimmers Association Inc.

###